

Increase Your EASC and Practice Bottom Line by Providing Hemorrhoidal Treatment

BY HARRY E. SARLES, JR., MD, FAGG

The Opportunity

Definitive treatment of hemorrhoids is something that, for the most part, gastroenterologists have abdicated to our surgical colleagues. As conventional surgical treatments have been associated with significant morbidity, prolonged recovery time and potential risks, gastroenterologists have been somewhat reticent to even make these referrals. Recent advances in hemorrhoid treatment technology have made this neglected area of care a viable and attractive option for gastroenterologists to provide treatment in their office or in their EASC. Offering hemorrhoid treatment allows gastroenterologists to provide more comprehensive care of their patients and presents additional opportunities to attract new patients, increase procedural volume, and maximize room utilization in the office or the EASC setting.

Hemorrhoid banding has been around as a procedure since the 1960's¹ and is one of the safest and most effective non-surgical modalities available. The skill set required to perform hemorrhoidal banding using the CRH-O'Regan Disposable Hemorrhoid Banding System (CRH Medical, Vancouver BC, CA) is a perfect match for the gastroenterology community at large. The procedure can be performed rapidly and painlessly for the patient without bowel preparation or anesthesia.

The technological advances demonstrated by the CRH-O'Regan Ligator allow for a very brief training session prior to gastroenterologists initiating care of their patients. I have adopted this new treatment technology in my practice at



Harry Sarles, Jr., MD, FAGG

Digestive Health Associates of Texas (DHAT) with remarkable initial success. We now have ten additional DHAT physicians trained to do the procedure in our practice. By including this new therapy, we have improved patient care and are now addressing the most common cause for rectal bleeding. We have strengthened our relationships with our patients and referring physicians alike. Clearly, the hemorrhoidal treatment part of our practice is also generating additional endoscopic procedures as well.

The Problem

Symptomatic hemorrhoids are a very common problem in the United States. It is estimated that 50% of the U.S. population will develop symptomatic hemorrhoids by the time they reach 50 years of age. The prevalence of symptomatic hemorrhoidal disease in the U.S. is 4%². Roughly one-third of these people will seek treatment, and well over \$250 million is spent on hemorrhoid care products each year. Patients and primary care physicians tend to avoid referral of these patients for definitive care, in large part because of the reputation of the surgical hemorrhoidectomy and the pain and disability that accompanies it. It is for these reasons that patients with peri-anal issues represent a dramatically underserved population, and this is all the basis of a tremendous opportunity for the gastroenterologist.

What are Hemorrhoids?

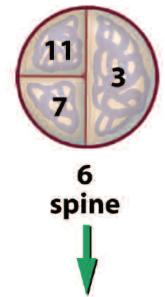
Anatomy: Hemorrhoidal cushions occur normally in the anal canal. They consist of connective tissue cushions surrounding the direct arteriovenous communications between the terminal branches of the superior rectal arteries and the superior, inferior, and middle rectal veins³. There

are typically three major hemorrhoidal cushions located in the left lateral, right anterior and right posterior locations. Minor cushions may also exist between these major ones. Normal hemorrhoidal cushions are felt to play a role in a patient's continence.

There is both internal and external hemorrhoidal tissue. The internal tissue is located proximal to the "dentate line" and is covered by a relatively insensate columnar epithelium, while the external tissue is located distal to the "dentate line" and is covered by squamous, sensate epithelium.

Pathology: The exact pathogenesis of prolapsing, symptomatic hemorrhoids is not clear, but many feel that chronic constipation, inadequate fiber or fluid intake, prolonged sitting on the toilet and straining to defecate all contribute to the problem³. Other risk factors include a family history and pregnancy. The hemorrhoidal tissue's connections to the underlying muscular layers become more tenuous, allowing the mucosa to progressively prolapse during defecation. The hemorrhoids will range in severity from simple bleeding tissue (Grade I), to tissue that prolapses on defecation but spontaneously reduces (Grade II), to tissue that must be manually reduced (Grade III), to the most severe hemorrhoids which cannot be readily reduced (Grade IV)⁴.

Perineal View



There are typically 3 dominant hemorrhoidal complexes, in the Left Lateral (3:00), Right Anterior (11:00) and Right Posterior (7:00) positions, when viewed in the supine position".

© I Cleator, 2008.

Hemorrhoidal symptoms include bleeding, itching, pain, and possible thrombosis. External hemorrhoidal changes may develop, and coexistent anal fissures and anal sphincter spasm are frequently present.

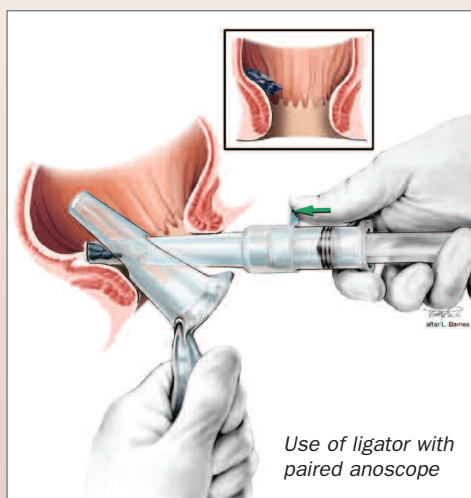
Treatment

The hemorrhoid ligation procedure using the O'Regan Hemorrhoid Ligator is highly effective and minimally invasive. The instruments are small, affording greater comfort for patients and better visibility for our physicians. The O'Regan Ligator is a modified syringe, which has a wide enough orifice to enable the suction of the hemorrhoidal tissue into the body of the syringe. An overlying sleeve is then engaged in order to release a band from the end of the device, strangulating the hemorrhoidal tissue at a point proximal to the dentate line.

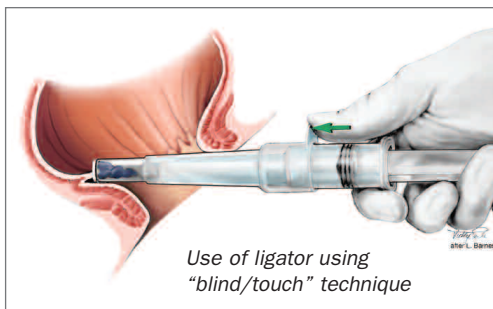


The CRH-O'Regan Hemorrhoid Ligator

As this tissue is insensate, the patient will only feel a sensation of pressure but not experience any pain. If the patient does feel pain, then the band can be adjusted or removed with an examining finger. Great care is taken to assure that the band is placed proximally, and that it does not include any of the muscular layer. These techniques help to assure the low risk of complications or pain. The device may be used in conjunction with a



Use of ligator with paired anoscope



Use of ligator using "blind/touch" technique

paired, slotted anoscope, or may be utilized using the "touch" technique without the anoscope⁵.

The banding procedure works by cutting off the blood supply to the hemorrhoid. This causes the hemorrhoid to shrink and fall off, typically within a day or so. During the first 24 hours, some patients may experience a feeling of fullness or a dull ache in the rectum. This can typically be relieved with an over-the-counter pain medication. However, a remarkable 99.8% of patients treated with this technology have no post-procedure pain⁶, and so the procedure has a ten-fold reduction in complications compared to traditional banding.

The procedure takes less than a minute to perform, it can be done in the office or the EASC setting, can be performed on all grades of hemorrhoids (including Grade III hemorrhoids, and most of those Grade IV hemorrhoids that can be reduced by the physician's intervention), and can be done without anesthesia or bowel preparation. In order to minimize complications, only one hemorrhoidal column is banded at a setting, and these three settings are held at two-week intervals.

The banding is sometimes performed in conjunction with a colonoscopy, but this must be done with caution. If a combined procedure is performed, the patient must be retained by the EASC until he or she is fully awake and sensate, as the patient's reaction to the banding is one of the keys that the band is properly placed. It is crucial that the patient be completely awake and pain free prior to being discharged in order to avoid post-procedure difficulties. Absolute contraindications include portal hypertension, pregnancy, and the use of anticoagulants such as warfarin.

Results

The most extensive study utilizing the O'Regan Ligator was carried out by Dr. Iain G. M. Cleator, Professor Emeritus of Surgery, University of British Columbia⁶. He studied 1852 consecutive patients, and, using the O'Regan Ligator, he banded one hemorrhoidal complex at each setting. His results were very impressive as he had a 99.1% success rate and a 0.9% complication rate, significantly better than results obtained with the banding of more than one column of hemorrhoids at a setting⁷. His patients demonstrated a 5% recurrence rate at two years.

Dr. Cleator's superior results were thought to be due to the gentle suction generated by the O'Regan Ligator, restricting the use of the bander to one hemorrhoidal column at a time, placement of the band a bit more proximally than typically done using some of the other banding technologies, and taking great care to make certain that the band did not include any of the underlying muscle.

Our Experience

We (DHAT) have been able to integrate this new technology into our practice with relative ease. Each of our physicians has been trained by CRH Medical Corporation using both didactic and live patient training sessions in our EASC. Physician trainers with extensive banding experience were provided by CRH Medical (www.crhcenter.com), and treatment protocols for patients with a wide variety of peri-anal difficulties were discussed. Post-training support is also provided for both our front and back offices, making the introduction of these services much easier for our practice.

Medicare reimbursement for hemorrhoidal banding in the Dallas area is \$212.95 in the office setting and \$282.00 in the EASC setting (\$161.02 for the physician component, and \$120.98 for the facility component). We are able to schedule four to five patients per hour. The cost for the equipment is \$75.00 per procedure. Additional office visit or consultation charges, along with other endoscopic procedures, may apply. I have chosen to integrate the procedure into my office practice; however, EASC integration is feasible depending upon the EASC availability and caseload. As a result of this

For 2 years, no one could identify the cause of my chronic diarrhea...

Until now.



PROBLEM:

In some adults with chronic diarrhea, a diagnosis remains elusive. On biopsy, these patients have specimens that appear normal on routine H&E staining. For this reason, they are diagnosed with IBS and are a challenge to manage...until now.

SOLUTION:

GI Pathology has identified a microscopic entity which may lead to a therapeutic solution. ID-ME employs a unique staining technique that allows our pathologists to render a novel diagnosis of Mastocytic Enterocolitis.

By treating Mastocytic Enterocolitis patients with drugs affecting mast cell mediator function, we have seen dramatic improvements in their symptoms and overall quality of life.

To learn more about Mastocytic Enterocolitis and ID-ME, please contact us at 1.888.2GI.PATH or visit us at DDW in Booth 2554.

GI Pathology has but one purpose and one passion – you, the gastroenterologist, and your patients.



150 Collins Street Memphis, TN 38112-3814
 † 888.244.7284 F 901.526.0791
 www.gipath.com



AD02 Rev. 04/07

previously unrecognized potential revenue stream, our practice is seeing an increase in revenue, both directly from these patient encounters as well as indirectly because of the fact that many hemorrhoid patients need additional gastrointestinal procedures and treatments. Hemorrhoidal banding has been a perfect match for my practice in this era of declining reimbursement and uncertain colorectal screening issues on the horizon.

This technology meets the mission of our practice—to provide our patients with the highest quality, comprehensive gastroenterologic care. Furthermore, it meets the business needs of our practice as it provides revenues that help to offset the losses that we see as a result of continued cutbacks from our third party payers. Additionally, it introduces a procedure to our practice that helps expand the menu of services that we provide. We feel that this should insulate our group's practice to some degree from any potential future shifts in current volumes of services that we provide and rely on—e.g., endoscopy and colonoscopy. The business plan for our practice is that if we see ten new patients per week for the hemorrhoidal banding treatment regimen, we would add an additional \$300,000.00 in net revenue per year by banding patients in lieu of the routine office visits that would be seen during the same time period.

Discussion

Hemorrhoidal disease is very common in our culture, with a prevalence rate of 4%. Patients tend to not seek care for these problems because of a sense of embarrassment and a fear of the treatment due to the reputation of the surgical hemorrhoidectomy. Use of a non-surgical approach to hemorrhoids expands the indication for treatment of these disorders, which had previously been reserved for only the most severe cases.

The CRH-O'Regan Disposable Hemorrhoid Banding System is a technology that can be utilized by the gastroenterologist in order to help care for these hemorrhoid patients. CRH Medical can provide the necessary physician training, as well as support the gastroenterologist's practice as required. This treatment can be done safely, quickly and effectively in an office or an EASC setting. Gastroenterologists, seeing many of these patients, are perfectly placed to be able to provide this care for their patients, ensuring the appropriate and continuous care of their patients. The ability to care for these patients in a GI's practice should lead to additional consultations and an expansion of the gastroenterologist's practice; and the ability to do these procedures in either the office or the EASC setting allows for additional flexibility in scheduling these patients, as well as the ability to more fully utilize the capacities of the facilities which are available.

References

- 1 Office Ligation Treatment of Hemorrhoids. *Dis Colon Rectum* 1963 6: 109-113, Barron J.
 - 2 Practice Parameters for the Management of Hemorrhoids (revised). *Dis Colon Rectum*. 2005 Feb;48(2):189-94. Cataldo P
 - 3 American Gastroenterological Association Technical Review on the Diagnosis and Treatment of Hemorrhoids. *Gastroenterology*. 2004 May;126(5):1463-73. Madoff R.
 - 4 Management of hemorrhoidal disease. *J S C Med Assoc* 1985 81 (7): 398-401. Banov L.
 - 5 Disposable device and a minimally invasive technique for rubber band ligation of hemorrhoids. *Dis Colon Rectum*. 1999 May;42(5):683-5. O'Regan, PJ
 - 6 Banding Hemorrhoids Using the O'Regan Disposable Bander. Business Briefing: US Gastro Rev 2005: 69-73. Cleator IG.
 - 7 Banding Hemorrhoids Using the O'Regan Disposable Bander. Single Center Experience. *J Gastrointestin Liver Dis*. 2007 June;16(2):163-165. Paikos D.
- Images are courtesy of Dr. Iain G M Cleator, MB, ChB, FRCS(c), FRCS(E), FACS, FRCS, and CRH Medical Corp (Vancouver, BC, CA)

Harry Eugene Sarles, Jr., MD practices at Digestive Health Associates of Texas, P.A. He is board certified in internal medicine and gastroenterology. After graduating from the University of Texas, he earned his medical degree at the University of Texas Medical Branch in Galveston. He also did his residency in Galveston. His fellowship in gastroenterology was completed at the VA Hospital in Phoenix.

Dr. Sarles has been in private practice since 1984. He belongs to numerous affiliations including AMA, AGA, American Society of Gastrointestinal Endoscopy and the Texas Society of Gastroenterology and Endoscopy. Dr. Sarles also holds an officer position in the American College of Gastroenterology. He has received numerous appointments and honors.