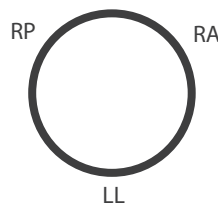


1. Nitroglycerin: Use the 0.125% NTG* ointment liberally, particularly with patients with anal sphincter spasm, pelvic floor spasm, and painful hemorrhoids in addition to anal fissures. Caution the patient to lie down when applying the ointment, and if they are hesitant to use their finger to administer the ointment into the anal canal, let them place the pea-sized amount of the ointment on a suppository and use it for an applicator of sorts. We will often prescribe a short course (2 weeks or less) of a steroid-containing suppository in this scenario, as the steroids will relieve some of the secondary inflammation present, providing symptomatic relief.

NITROGLYCERIN IS YOUR FRIEND! One of the most frequently overlooked issues is that of a coexistent fissure in your symptomatic patients. **YOU DO NOT NEED TO SEE A FISSURE IN ORDER TO KNOW THAT IT EXISTS!** If the patient is tender in the midline (usually posteriorly), and if the patient does not have a fistula or an abscess, then for all practical purposes, **THEY HAVE A FISSURE!** If you feel an area of thickening, a “ridge”, a “seam”, or any other evidence of prior or concurrent inflammation in the midline – **THEY HAVE A FISSURE!** Failure to address this will severely impact your success rate in treating these patients. Dr. Cleator goes as far as to give NTG to virtually all of his patients, as he notices that there is less pain experienced by the patients, and he feels that the resultant ulcers heal a bit quicker with routine use. **TRY TO ESTABLISH A RELATIONSHIP WITH A COMPOUNDING PHARMACY NEAR YOU!** We have several that we deal with that are aware of the meds that we will be prescribing, and because they are able to mix up the NTG* in bulk, it results in a significant cost savings to the patients.

2. Thrombosed external hemorrhoids: These only need an I&D if they present within the first 24-48 hours (some use 72 hours at the outside) . . . if they have a longer history than that, then there is little need to do anything to them other than to treat the patient with topical anesthetics and strongly consider using NTG. If you choose to I&D the thrombosis, we would be happy to give you the technique. Should you choose to send these patients out, consider sending the patients to a surgeon only if they can be seen in the first 24 – 48 hours (certainly within 72 hours) after the onset of their symptoms.

3. Placement of typical hemorrhoids: Left Lateral, Right Anterior and Right Posterior. In the Left Lateral Decubitus position, that would translate to the following:



4. “Blind” placement of the band: This is truly not “blind”, as you have already seen and palpated the hemorrhoids. Use an examining finger to help introduce the bander, so that the forward edge of the bander does not catch any of the soft tissues, which would cause discomfort to the patient. Advance the bander a bit further in than you will ultimately need it to be, and pass it along the direction of the rectal lumen (usually parallel to the patient’s spine). Draw the Ligator back to the point where the band will be deployed, and only then “point” the Ligator towards the hemorrhoid column in question. This point can be estimated by utilizing the ridge on the “band pusher” as if it is at the anal verge, then you should be in a satisfactory position, at least 2 cm proximal to the dentate line. The ability to sense that the tip of the bander is at the “L-angle” of the rectum will help to confirm the placement of the bander.

5. Do NOT “push” the ligator up towards the pile in question, as if to “reach out” to the tissue, as this often makes it more difficult to obtain a satisfactory amount of tissue. Simply aiming the device in the correct direction will allow that tissue which is most prominent and already filling the lumen to be captured by the syringe. LET THE LIGATOR DO ALL OF THE WORK FOR YOU – the more effort that you put into obtaining tissue, the less successful you will be!! If you do not obtain tissue on this first positioning of the ligator (evidenced by the syringe plunger retracting when letting go of it after aspirating), do not push on the ligator, but rather just increase the angle at which you are holding the device.

6. After deploying the band, a digital exam is performed to make certain of four things:

- You have banded a sufficient amount of tissue
- There is no muscular entrapment
- The diameter of the neck of the “polyp” that was created is fairly narrow, minimizing the size of the resultant ulcer, and minimizing the chance of post banding bleeds.
- The patient does not have pain, or a “pinching” sensation.

7. Manipulation of the banded pile: We recommend that you manipulate the banded pile routinely after deploying the band in order to assure that the banded tissue is free from the muscularis. The pile should slide and move much like the skin on the dorsum of the hand, rather than like the skin on the palm of the hand. Care should also be taken to make certain that there is no entrapment of surrounding mucosa away from the pile. A sense that the band has a fairly narrow diameter, and that the “neck” of the pile makes the tissue feel as if it is a small pedunculated polyp will help to minimize the risks of pain or bleeding. IF THE PATIENT HAS PAIN AFTER BANDING then a more “vigorous” manipulation is required, and using the finger to “pull” the base of the banded tissue from the right, the left, and from the proximal side of the pile, as well as “pushing” the pile from below will typically free up the necessary tissue and relieve the discomfort. If the patient is still uncomfortable, the examining finger should be used to “roll” the band a bit. If the band was placed too “low”, and below the dentate line, then do not try to “adjust” the band, rather pop it off, using two fingertips if necessary.

8. Have your patient wait around a few minutes after a banding, just to make certain that they don’t feel a “pinch”. If there is a pinching sensation, then you must adjust the band, or pop it off if necessary . . . otherwise that pinch will become more severe. If the patient leaves without that “pinch”, then less than 1% of your patients should experience significant pain.

9. If the patient has a fissure (usually posterior, infrequently anterior), stay away from that hemorrhoid until the fissure is significantly healed, even if the that hemorrhoid is the most severe one. Start elsewhere, and come back to the hemorrhoid which was proximal to the fissure in a subsequent visit. The same holds true for the patient with a thrombosed external hemorrhoid. Stay away from the corresponding internal hemorrhoid until the external component improves. If the patient is really miserable with symptoms from either a fissure or thrombosis, then begin medical management of these problems and defer banding for a week or two.

10. Band one column of hemorrhoids at a sitting in an effort to minimize complications. Avoid banding anyone on Coumadin or Plavix, or with some form of active proctitis. Also avoid pregnant women and patients with signs of portal hypertension.

11. Realize that many people will have cutaneous yeast infections in response to the mucoid deposition on the perianal skin from their internal hemorrhoids, and the constant wiping and trauma to the skin that occurs . . . use antifungal creams liberally (I use Lotrisone cream with an added corticosteroid). If this is not successful, then I will utilize a 2 or 3 day course of Diflucan. Use a product such as Balneol in order to help clear the mucoid material, and take care of the patient’s hemorrhoids in order to prevent additional symptoms from occurring.

12. TAKE ADVANTAGE OF THE SUPPORT OFFERED BY CRH! Feel free to utilize our 24/7 professional support along with the marketing, operational, coding, billing and contracting support that is available to you from CRH. We are also happy to plan for a repeat training session for you after you’ve had some experience with the Technology. Most that arrange for these follow-up session report that there was a significant benefit realized. This is all provided at no cost to you, so please take full advantage of it.