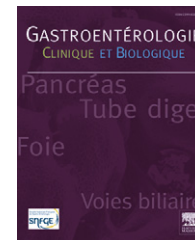




Disponible en ligne sur
 ScienceDirect
 www.sciencedirect.com

Elsevier Masson France

 www.em-consulte.com



EDITORIAL

Risk of bleeding following hemorrhoidal banding in patients on antithrombotic therapy

Risque de saignement après ligature élastique pour hémorroïdes chez des patients traités par anticoagulants ou antiagrégants plaquettaires

Introduction

Hemorrhoidal banding is an office procedure for the treatment of grade 1 to 3 internal hemorrhoids. It has been shown to be a safe and relatively effective way to treat minimally symptomatic hemorrhoids without a formal operation. Risks associated with hemorrhoidal banding have been well described and range from bleeding, urinary retention, recurrence and, rarely, sepsis or death. The overall risk of complications following placement of a hemorrhoidal band ranges from 3.5 to 10% [1–6]. Bleeding is the most common complication associated with hemorrhoidal banding, with minor or insignificant bleeding being reported in as many as 1.7% and major or significant bleeding in 0.8% of patients [1–5].

Recommendations for patients who are candidates for rubber band ligation but are on antithrombotic therapy have never been formally evaluated. Some studies have shown subsets of patients with a much higher bleed rate, ranging from 7 to 25% [1,2,7], while on antithrombotic medication. Many authors recommend not banding any patient until they have been off their medication for 7–10 days before the banding, followed by a further 7–10 days thereafter [8–10]. This treatment algorithm leads to multiple office visits for diagnosis and subsequent treatment and an increased time off their medication which may lead to a greater risk of stroke, myocardial infarction, or deep venous thrombosis [11–15].

Prophylaxis against heart disease and stroke, treatment for deep venous thrombosis and the recent placement of cardiac stents are the most common reasons why patients require some form of anticoagulant or antiplatelet therapy. Patients taking aspirin for coronary artery disease have been reported to have a new coronary event 4.1% of the time when stopping their aspirin [14]. The risk of stroke in

high-risk patients who discontinued their antiplatelet therapy has been reported as high as 4.9% [13].

Our practice has been to see and evaluate a patient with symptomatic hemorrhoids, discuss the risk and benefits of a banding procedure and to perform the banding immediately in the office. Patients then hold their medication for 10 days if taking aspirin or clopidogrel bisulfate and seven days if taking warfarin. The risk of bleeding following hemorrhoidal banding is highest as the mucosa sloughs off at 5–10 days. The described treatment algorithm allows for greatest thrombotic activity at the time of greatest risk of bleeding while limiting the time off therapy.

Our experience

A review of our hemorrhoidal bandings revealed a total of 605 bands placed on 364 patients while on antithrombotic or antiplatelet therapy, including aspirin 81 mg, aspirin 325 mg, non-steroidal anti-inflammatory drugs, warfarin and clopidogrel bisulfate 75 mg. A majority of patients were on thrombotic prophylaxis for increased risk of stroke or myocardial infarction. Complications occurred in 44 of the 605 bandings (7.3%). There were 23 (3.7%) bleeding complications, five (0.8%) patients developed urinary retention, 14 (2.3%) patients who complained of moderate to severe pain and two (0.3%) patients reported fever/chills following the banding. There were no deaths.

Of the bleeding complications, 17 (2.7%) were considered insignificant, requiring no further therapy. Six (0.9%) were considered significant, requiring a visit to the emergency room, admission to the hospital or transfusion of blood products. None of these values varied statistically from what had previously been reported in the literature [1,2,6]. However, six bleeding episodes occurred in 18 patients who underwent

a total of 35 bandings while taking clopidogrel. Three (8.6%) patients had significant bleeds and three (8.6%) had insignificant bleeds. Twelve of these patients were taking both aspirin and clopidogrel. Two of the significant and one of the insignificant bleeding episodes occurred in patients taking both aspirin and clopidogrel. While there was an insufficient sample size to reach a statistical conclusion, it was concerning that such a high percentage of patients on clopidogrel bled following banding.

Discussion

The rationale for our method of managing these patients follows the expected effect on platelets and anticoagulation of the particular drug the patient is taking. The greatest risk for bleeding following banding is from mucosal sloughing, typically from 5–10 days after ligation [8]. By holding the antiplatelet drugs at the time of banding, much of their effect will be greatly diminished at roughly this critical time. By not stopping the drug prior to the procedure, we also cut down on the time patients will be off their antithrombotic medication. Time off their medication increases their risk for stroke, myocardial ischemia or a complication of any other medical condition for which they are taking their medication. Once re-initiated, antiplatelet therapy rapidly achieves significant antiplatelet activity. This may minimize risk of thrombotic events. With warfarin, stopping the drug at time of banding will usually allow normalization of international normalized ratio (INR) at 3–5 days. Starting it at the regular scheduled dose again at 7 days means full effect will probably not be realized until sometime after 10 days. This approach minimizes the anticoagulant effect during the critical 5–10 days postband bleeding risk.

The risk of bleeding or any complication following a hemorrhoidal band is quite low. However, since there are an increasing number of patients presenting to an office setting to be evaluated for bleeding while on antithrombotic and/or antiplatelet therapy, the timing of office based procedures needs to be carefully considered. With an increase of new antithrombotic agents in the management of patients with cardiovascular, cerebrovascular and peripheral vascular disease, surgeons now have to contend with either an increased risk of bleeding or the delay of a procedure in these patients. The CAPRIE trial demonstrated that clopidogrel is more effective and safer than aspirin in reducing adverse cardiovascular events in patients with atherosclerosis [16]. Thus, a growing proportion of patients being seen today by surgeons are taking antiplatelet and anticoagulant medications.

The discontinuation of antithrombotic medication for 1 week before and up to 2 weeks after a banding appears to be unnecessarily long. A repeat office visit, following a diagnosis of hemorrhoids suitable for banding so antithrombotic medication can be stopped, appears to be inefficient and costly. With a shortened timeline off medication and no delay for discontinuation of medication, our risk of significant bleeding was less than 1%. If clopidogrel was not included, the risk of bleeding was less than 0.5%. When coupled with the increased risk of possible stroke [12] or rebound myocardial infarction [14] following discontinuation of antiplatelet and anticoagulation therapy, it would

appear that holding antithrombotic medication longer than is necessary may be more dangerous than the risk of bleeding following hemorrhoidal banding.

Conclusion

If it is determined that bleeding from hemorrhoids is a significant risk for a patient on antithrombotic therapy and banding is considered the most effective therapy, then the stoppage of antithrombotic therapy should be kept to the least amount of time possible. The use of the timeline described here, withholding antiplatelet therapy for 10 days and anticoagulation therapy for 7 days, may satisfy that requirement while not leading to an increased risk of a bleeding complication from the banding. Patients taking clopidogrel, while not statistically significant, did trend toward a greater risk of bleeding than the other groups. These patients may need to stop their medications prior to banding. Always, the risk of medical complications associated with cessation of antithrombotic and antiplatelet therapy needs to be considered and balanced against actual medical risks related to bleeding in the treatment planning for patients with symptomatic hemorrhoids.

References

- [1] Bat L, Melzer E, Koler M, Dreznick Z, Shemesh E. Complications of rubber band ligation of symptomatic internal haemorrhoids. *Dis Colon Rectum* 1993;36:287–90.
- [2] Iyer VS, Shrier I, Gordon PH. Long term outcome of rubber band ligation for symptomatic primary and recurrent internal hemorrhoids. *Dis Colon Rectum* 2004;47:1367–70.
- [3] Lau WY, Chow HP, Poon GP, Wong SH. Rubber band ligation of three primary hemorrhoids in a single session. *Dis Colon Rectum* 1982;4:336–9.
- [4] Mattana C, Maria G, Pescatori M. Rubber band ligation of hemorrhoids and rectal mucosal prolapse in constipated patients. *Dis Colon Rectum* 1989;32:372–5.
- [5] Chew SS, Marshall L, Kalish L, Tham J, Grieve DA, Douglas PR, et al. Short-term and long-term results of combined sclerotherapy and rubber band ligation of hemorrhoids and mucosal prolapse. *Dis Colon Rectum* 2003;46:1232–7.
- [6] Wechter DG, Luna GK. An unusual complication of rubber band ligation of hemorrhoids. *Dis Colon Rectum* 1987;30:137–40.
- [7] Marshman D, Huber Jr PJ, Timmerman W, Simonton CT, Odom FC, Kaplan ER. Hemorrhoidal ligation. A review of efficacy. *Dis Colon Rectum* 1989;32:369–77.
- [8] Corman ML. *Colon and rectal surgery*. 5th edition Lippincott Williams & Wilkins; 2002, p. 192.
- [9] Gordon PH, Nivatongs S. *Principles and practice of surgery for the colon, rectum and anus*. 2nd ed. St Louis Missouri: Quality Medical publishing Inc; 1999, p. 200.
- [10] Beattie GC, Rao MM, Campbell WJ. Secondary haemorrhage after rubber band ligation of haemorrhoids in patients taking clopidogrel—a cautionary note. *Ulster Med J* 2004;73:139–41.
- [11] Sibon I, Orgogozo JM. Antiplatelet drug discontinuation is a risk factor for ischemic stroke. *Neurology* 2004;62:1187–9.
- [12] Maulaz AB, Bezerra DC, Michel P, Bogousslavsky J. Effect of discontinuing aspirin therapy on the risk of brain ischemic stroke. *Arch Neurol* 2005;62:1217–20.
- [13] Ho PM, Peterson ED, Wang L, Magid DJ, Fihn SD, Larsen GC, et al. Incidence of death and acute myocardial infarction

- associated with stopping clopidogrel after acute coronary syndrome. *JAMA* 2008;299:532–9.
- [14] Ferrari E, Berboni P, Baudouy M. Coronary syndromes following aspirin withdrawal. *Chest* 2003;125:1485.
- [15] Colet JP, Himbet F, Steg PG. Myocardial infarction after aspirin cessation in stable coronary artery disease patients. *Int J Cardiol* 2000;76:257–8.
- [16] CAPRIE steering committee. A randomized, blinded trial of clopidogrel versus aspirin in patients at risk of ischaemic events. *Lancet* 1996;348:1329–39.

R.S. Nelson*

A.G. Thorson

Colon and Rectal Surgery, Colon and Rectal Surgery Inc, Suite 100, 9850 Nicholas Street, Omaha, NE68114, United States

* Corresponding author.

E-mail address: [warmerinne@cox.net](mailto:warmierinne@cox.net)

(R.S. Nelson)

Available online 12 June 2009